


Vaginal natural orifice transluminal endoscopic total hysterectomy (vNOTES)

Ilnur Irekovich Musin,¹ Edvard Alexandrovich Berg ¹,
Alfiya Galimovna Yashchuk,¹ Gulnaz Khanifovna Murtazina,¹
Daniil Nikolaevich Ovsiuk,¹ Zarina Tagirovna Gimaeva²

► Additional supplemental material is published online only. To view, please visit the journal online (<https://doi.org/10.1136/gocm-2024-000015>).

¹Obstetrics and Gynecology Department №2, Bashkir State Medical University, Ufa, Russia
²Gynecology Department (University Clinic), Bashkir State Medical University, Ufa, Russia

Correspondence to

Dr Edvard Alexandrovich Berg,
Obstetrics and Gynecology,
Bashkir State Medical University,
Ufa, Russia;
aig.eaberg@gmail.com

Received 9 March 2024

Accepted 14 May 2024

Published Online
First 7 June 2024

A total hysterectomy is a common procedure. According to published data, in the European Union, laparoscopic and laparoscopic-assisted hysterectomies are performed more frequently than abdominal hysterectomies.¹ A new technique in endoscopic surgery is the natural orifice approach—vaginal natural orifice transluminal endoscopic surgery (vNOTES). Performing a hysterectomy using the vNOTES method has a number of advantages compared with the traditional one, including a decrease in the intensity of pain in the early postoperative period, the absence of a cosmetic defect on the anterior abdominal wall and improved visualisation, which reduces the risk of intraoperative complications.² This type of surgery is a combination of vaginal access as well as single-port endoscopic technique. Due to the vaginal approach, vNOTES is associated with no risk of infection, postoperative hernia or dehiscence of sutures on the anterior abdominal wall compared with the laparoscopic one.^{2,3}

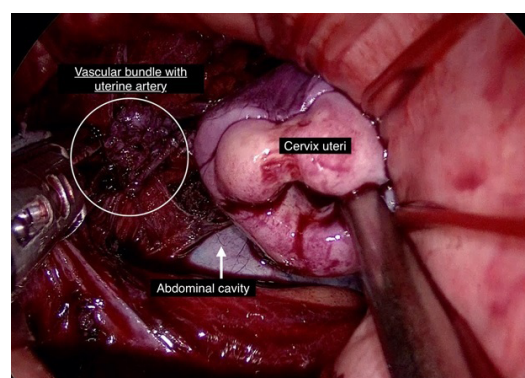


Figure 1 Ligation of the vascular bundle containing the uterine artery with an electrocautery instrument. Cervix is in craniolateral position.

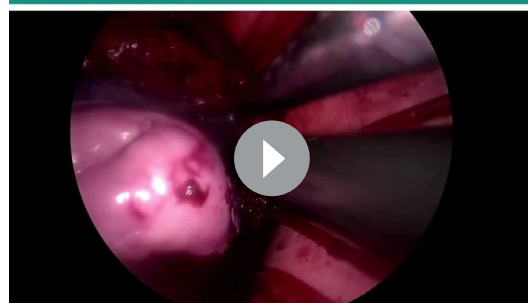
The operation was carried out at the clinical base of Bashkir State Medical University, Ufa, Russia. The course of the operation involves two stages: vaginal and laparoscopic (video 1).

The vaginal stage includes anterior and posterior colpotomies, the intersection of the cardinal and uterosacral ligaments and the installation of a port for subsequent laparoscopy via vaginal access.

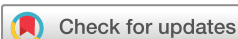This is followed by the installation of the port and the beginning of the laparoscopic stage of the operation. In our practice, we use a four-port laparoscopic system. The vNOTES operation does not require the Trendelenburg position, as with traditional laparoscopy; we only use it for patients with a body mass index greater than 35.

The laparoscopic stage includes the intersection of the uterine arteries, round ligaments and the ovarian ligament or infundibulopelvic ligament, as well as the revision of the pelvic organs (figure 1).

GOCM
Gynecology and Obstetrics Clinical Medicine



Video 1 The vaginal natural orifice transluminal endoscopic surgery method allows additional visualisation of the surgical field and enables tubectomy, adnexectomy and cystectomy, which are limited to perform with traditional vaginal access.



© Author(s) (or their employer(s)) 2024. Re-use permitted under CC BY-NC. No commercial re-use. See rights and permissions. Published by BMJ.

 @GynecologyGOCM

If a tumour is present, it is removed by endobag in compliance with the rules of ablastics. If there are indications for uterine appendage removal, it can be easily done via the vNOTES approach (video 1). The endoscopic stage ends with a haemostasis check, deflating and removing the portal system. Finishing the operation with peritonisation and suturing of the vaginal mucosa. The vaginal stage may include various colpoperineal plastic surgeries, simultaneously.

Contributors IIM and EAB performed the surgery and recorded the video. DNO edited the video. ZTG and GKM wrote the draft. AGY reviewed the draft and supervised the final video. All authors approved the final edition. EAB is the author responsible for the overall content as the guarantor.

Funding The authors have not declared a specific grant for this research from any funding agency in the public, commercial or not-for-profit sectors.

Disclaimer Conclusion of the local ethics committee of BSMU the ongoing scientific research complies with generally accepted moral standards, the requirements of respecting human rights, interests and personal dignity of the patient participating in the study (Bashkir State Medical University Local Ethics Committee, Protocol No. 10 15.12.2021).

Competing interests IIM has served as an editorial member of GOCM. All other authors declare no competing interests.

Patient and public involvement Patients and/or the public were not involved in the design, or conduct, or reporting, or dissemination plans of this research.

Patient consent for publication Consent obtained directly from patient(s).

Ethics approval This study involves human participants and was approved by the Bashkir State Medical University Local Ethics Committee, Protocol No. 10 15.12.2021. Participants gave informed consent to participate in the study before taking part.

Provenance and peer review Not commissioned; externally peer reviewed.

Data availability statement Data are available upon request.

Supplemental material This content has been supplied by the author(s). It has not been vetted by BMJ Publishing Group Limited (BMJ) and may not have been peer-reviewed. Any opinions or recommendations discussed are solely those of the author(s) and are not endorsed by BMJ. BMJ disclaims all liability and responsibility arising from any reliance placed on the content. Where the content includes any translated material, BMJ does not warrant the accuracy and reliability of the translations (including but not limited to local regulations, clinical guidelines, terminology, drug names and drug dosages), and is not responsible for any error and/or omissions arising from translation and adaptation or otherwise.

Open access This is an open access article distributed in accordance with the Creative Commons Attribution Non Commercial (CC BY-NC 4.0) license, which permits others to distribute, remix, adapt, build upon this work non-commercially, and license their derivative works on different terms, provided the original work is properly cited, appropriate credit is given, any changes made indicated, and the use is non-commercial. See <http://creativecommons.org/licenses/by-nc/4.0/>.

ORCID iD

Edvard Alexandrovich Berg <http://orcid.org/0000-0002-2028-7796>

REFERENCES

- 1 Housmans S, Stuart A, Bosteels J, *et al.* Standardized 10-step approach for successfully performing a hysterectomy via vaginal natural orifice Transluminal endoscopic surgery. *Acta Obstet Gynecol Scand* 2022;101:649–56.
- 2 Simms KT, Yuill S, Killen J, *et al.* Historical and projected hysterectomy rates in the USA: implications for future observed Cervical cancer rates and evaluating prevention interventions. *Gynecol Oncol* 2020;158:S0090-8258(20)31099-4:710–8.
- 3 Lerner VT, May G, Iglesia CB. Vaginal natural orifice Transluminal endoscopic surgery revolution: the next frontier in gynecologic minimally invasive surgery. *JSL* 2023;27:e2022.00082.