

Review Article

Retroperitoneal para-aortic ectopic pregnancies: A review of reported cases

Junxiang Ren, Hongjing Han*



Department of Obstetrics and Gynecology, Peking University People's Hospital, Xicheng District, Beijing, 100044, China

ARTICLE INFO

Keywords:

Retroperitoneal pregnancy
Ectopic pregnancy
Para-aortic
Treatment

ABSTRACT

Objective: To gain insights into the diagnosis and treatment of retroperitoneal para-aortic ectopic pregnancies (RPEP).

Methods: We conducted a review of the existing literature from the web of science, PubMed, and CNKI using the search terms "ectopic pregnancy" and "retroperitoneal." The present review follows the Preferred Reporting Items for Systematic Reviews and Meta-Analysis (PRISMA) guidelines.

Results: After applying the inclusion and exclusion criteria, we included a total of 54 relevant works, encompassing 55 cases. The studies have revealed that a history of artificial abortion, embryo transfer, salpingectomy, and uterine cavity operation, accounted for 65.5 % (36/55) of the cases. Typical symptoms of RPEP include abdominal pain (43.6 %, 24/55) and vaginal bleeding (36.4 %, 20/55), with only 32.7 % (18/55) of cases being asymptomatic. The most common sites of RPEP are the abdominal aorta and the inferior vena cava (74.5 %, 41/55). There were no statistically significant differences in the incidence of acute abdomen, diameter of the pregnancy sac, number of surgeries, and the time for postoperative hCG to normalize in different pregnant site. The most effective imaging examination for RPEP was found to be abdominal ultrasound (72.7 %, 40/55), and the most commonly used treatment method was laparoscopy surgery (55.3 %, 21/38).

Conclusion: It is crucial to consider the possibility of RPEP when a pregnancy mass cannot be located during routine examinations. Expanding the scope of the scan may significantly expedite diagnosis and treatment.

1. Introduction

The occurrence of ectopic pregnancies is reported to be 11 cases in every 1000 pregnancies, with ectopic tubal pregnancies accounting for 95 % of these cases, and retroperitoneal ectopic pregnancies (REP) comprising only 1.3 %.¹ However, despite its low incidence, the mortality rate for REP is 8 times higher than that of tubal pregnancies due to its unique location, diagnostic challenges, delayed treatment, and increased operative risk.² Retroperitoneal para-aortic ectopic pregnancy (RPEP) is a type of retroperitoneal pregnancy, which usually refers to the pregnancy sac adheres to large aortics (In addition to the abdominal aorta, the inferior vena cava and iliac vessels were also discussed in this article). This condition presents significant challenges in clinical practice. Untreated cases can lead to severe consequences such as retroperitoneal bleeding, shock, and disseminated intravascular coagulation (DIC).

Surgical procedures near major celiac vessels carry the added risk of intraoperative bleeding.

Furthermore, the published year chart depicting indicates a recent increase in the incidence of RPEP (Table 1). Although there have been several reviews on REP, a clear consensus on REP, especially concerning dangerous RPEP, is still lacking worldwide. To facilitate rapid diagnosis and effective treatment of RPEP, we conducted a comprehensive review of reported literature from 1973 (when the first case of RPEP was published) to July 2023. This review summarizes and analyzes the location, clinical symptoms, diagnosis, and treatment of RPEP, aiming to assist clinicians in diagnosing and making decisions related to RPEP.

2. Materials and methods

We conducted a comprehensive search in the Web of Science,

* Corresponding author. Department of Obstetrics and Gynecology, Peking University People's Hospital, Xicheng District, Beijing, 100044, China
E-mail address: han_hhj@126.com (H. Han).



PubMed, and CNKI databases using the search terms "(retroperitoneal [Title/Abstract]) AND (Ectopic pregnancy [Title/Abstract])," and supplemented related cases through literature tracking as Fig. 1. The aim was to identify relevant literature focusing on cases where the pregnancy sac is located adjacent to large retroperitoneal vessels.

The inclusion criteria were as follows: (1) the literature was in English or Chinese, (2) the pregnancy sac was located next to the retroperitoneal plates, (3) complete clinical data were available in Table 1. On the other hand, the exclusion criteria were as follows: (1) literature in languages other than English or Chinese, (2) lacking clear diagnostic criteria, (3) missing important clinical data.

We extracted pertinent information from the cases of RPEP, including patients' age, period of amenorrhea, method of conception, and more (see Table 1). For clarification: (1) the period of amenorrhea refers to the time interval from the first day of the last menstrual period to the day of diagnosis; for In Vitro Fertilization (IVF) patients, it is the number of days after transplantation plus 17 or 19. (2) β -human chorionic gonadotropin (hCG) level indicates the latest blood test result before treatment. (3) The blood hCG normalization time refers to the interval between the operation and the point at which hCG levels return to a positive value in the blood. (4) The selection of all literature and data was independently carried out by two authors, and any discrepancies in the results were resolved through mutual checking and discussion between the two authors.

SPSS 26.0 software was used for statistical analysis. A significance level of $P < 0.05$ was considered statistically significant. Continuous data were expressed as mean \pm standard deviation ($\bar{x} \pm s$). Normality of data was assessed using the Shapiro-Wilk test. For between-group comparisons of normally distributed data, an independent samples *t*-test was used. For data that did not follow a normal distribution or had unequal variances, the non-parametric Mann-Whitney *U* test was employed. Categorical data were presented as *n* (%), and between-group comparisons were conducted using the chi-square test.

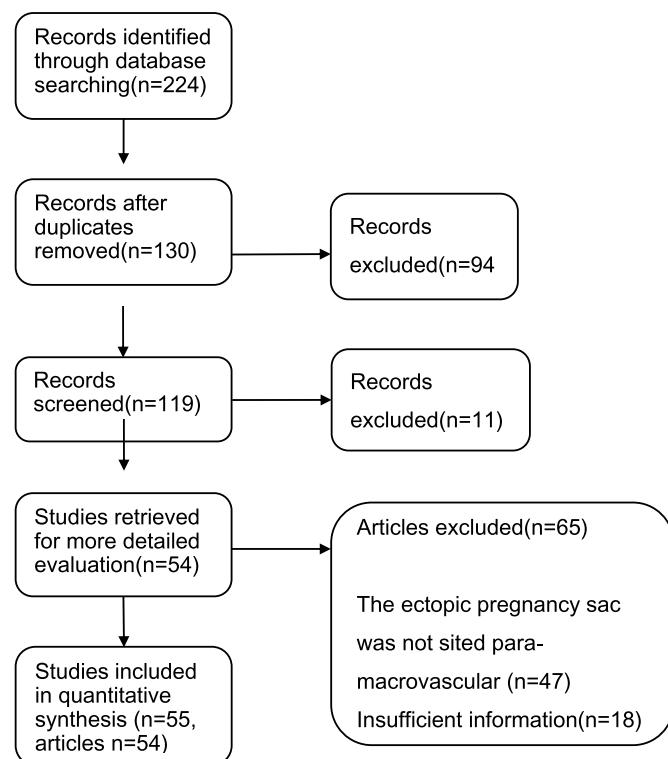


Fig. 1. The flow diagram to summarize the stages of the review.

3. Results

3.1. Literature search and screening results

We identified a total of 224 relevant works of literature, which included cases of RPEP. Subsequently, we excluded 170 cases based on information from hospitals and patients (Fig. 1). As a result, we obtained 54 unique works of literature, encompassing 55 subjects. Out of these, 26 reports were in English, and 29 were in Chinese. Notably, there were 2 cases managed conservatively among the identified cases.

3.2. General information

Based on the data gathered from the literature review (Table 2), the average age of 55 cases is 31.0 years, and the average gestational week is 55.6 day. It appears that patients with specific risk factors, including a history of artificial abortion (17 cases through unilateral salpingectomy, 11 cases through bilateral salpingectomy), embryo transfer, salpingectomy, and uterine cavity operation, accounted for 65.5 % (36/55) of the cases.

The main symptoms of RPEP are abdominal pain (43.6 %) and vaginal bleeding (36.4 %), with only (32.7 %) of cases being asymptomatic. To diagnose RPEP, the most common examinations include abdominal ultrasound (72.7 %), CT (computed tomography) scans, and MRI (magnetic resonance imaging). There are 13.6 % (3/22) of patients with fetal heartbeat then ruptured, 27.3 % (3/11) of patients without fetal heartbeat then ruptured (22 cases had fetal heartbeat and 11 cases without, other 22 cases did not mention). The literature review revealed that a significant portion, 65.5 % (36/53) of the patients underwent unnecessary invasive procedures, such as preoperative uterine curettage and secondary abdominal surgery.

3.3. Pregnancy sites and classification of RPEP

In our study, we examined the pregnancy sacs located in close proximity to the large retroperitoneal vessels while reviewing the literature on retroperitoneal pregnancy. However, we excluded cases found in the Douglas fossa, sacral ligament, and broad ligament. The findings revealed that the most frequent sites of RPEP were the abdominal aorta and the inferior vena cava (74.5 %, 41/55). Other relatively uncommon locations (25.5 %, 14/55) included the bifurcation of the common iliac artery, internal and external iliac vessels, and other less frequently reported locations. The difference between the RPEP located near the abdominal aorta, inferior vena cava, and iliac vessels is detailed in Table 3. The preoperative hCG levels in the iliac vessel adjacent group were lower than those in the groups adjacent to the abdominal aorta and inferior vena cava (40445 ± 30081 VS 18202 ± 16681 , $P=0.027$). However, there were no statistically significant differences in the incidence of acute abdomen, diameter of the pregnancy sac, number of surgeries, and the time for postoperative hCG to normalize ($P > 0.05$).

3.4. Treatment

In this study, we examined a total of 10 conservative cases of RPEP, out of which two cases (20 %, 2/10) were successfully managed, one case resulted in rupture, and seven cases showed ineffective conservative treatment. The conservative methods used for RPEP included intramuscular and interventional methotrexate (MTX) injection, as well as oral mifepristone. The two successful cases were asymptomatic and had amenorrhea for 68–73 days, with β -hCG levels exceeding 90,000IU/L. The diameter of the pregnancy sac in these cases ranged from 4.2 cm to 4.6 cm. Among them, one case had a fetal heartbeat. After 100–120 days, the β -hCG levels returned to normal. In the eight cases where conservative treatment failed, the patients had amenorrhea for 47–63 days, and β -hCG levels fluctuated between 24,000 and 82,000IU/L. The diameter of the gestational sac in these cases ranged from 2 cm to 5.4 cm. One case

Table 1
Information on all reported RPEP pregnancy patients.

First Author/Year	Age	Site of ectopic pregnancy	Mode of conception	Period of amenorrhea (days)	Times of artificial abortion	Fetal heartbeat	Curetage before surgery	Emergency/shock	Symptoms	Cutting Fallopian tube	Diameter of GS	Diagnosis methods	hCG before treatment (IU/L)	The ultimate treatment	Surgery times	hCG to normal (days)
Tan QH,2016 ³	26	Left inferior kidney and junction of the ureter and abdominal aorta	NP	78	1	NM	Yes	Yes	Left waist and abdominal pain + Vaginal spotting	1	3	CT + MRI	212.18	Laparotomy	1	14
Lin XJ,2008 ⁴	19	Adjacent to right internal and external iliac vessels	NP	49	0	NM	Yes	No	Right lower abdominal pain	0	4	TAS	267.31	Laparotomy	2	3
Liang CH,2014 ⁵	26	Near Abdominal aorta, gonadal vessels, and left renal vein	ART	51	0	NM	No	No	Left waist pain	2	6.5	CT	1076	Laparotomy	2	>7
Sun N,2021 ⁶	32	Right iliac perivascular	NP	42	NM	NM	No	No	Abdominal pain + Vaginal spotting	1	3	TAS + laparoscopy	3428	Laparoscopy	1	12
Li L,2018 ⁷	36	Anterior of abdominal aorta and inferior vena cava	ART	54	NM	NM	Yes	No	Asymptomatic	1	2	CT	4212	Laparotomy	2	>5
Reid F,2003 ⁸	28	Bifurcation of common iliac artery	ART	70	0	Yes	Yes	Yes	Vaginal spotting + Left fossa pain	2	6	Laparoscopy Exploration	5500	Laparotomy	2	10
Wu XW,2021 ⁹	30	The medial side of the right external iliac artery	NP	51	NM	Yes	No	No	Asymptomatic	0	1.2	During surgery: TAS + laparoscopy	6002.3	Laparoscopy	1	NM
Bian J,2019 ¹⁰	32	Bifurcation of common iliac artery	ART	44	0	NM	No	No	Asymptomatic	1	2	TAS	6079	Laparoscopy	1	>7
Qiu JN,2016 ¹¹	30	Close to the surface of inferior vena cava	NP	50	NM	Yes	No	Yes	Abdominal pain + Vaginal spotting	0	4	TAS	17599	Laparoscopy	1	21
Liu Y,2015 ¹²	27	Close to the right front of the abdominal aorta, near the branch of the iliac artery	ART	46	0	Yes	No	No	Asymptomatic	2	2.5	TAS	18210	Laparoscopy	1	NM
Lang TY,2021 ¹³	37	The medial side of the left external iliac artery	NP	50	0	Yes	No	No	Vaginal spotting	0	3	TAS + MRI	18955	Laparoscopy	1	15
Jin WY,2019 ¹⁴	33	At the level of the inferior mesenteric artery and left side of the abdominal aorta	NP	50	NM	NM	No	No	Asymptomatic	2	3	TAS	20220.3	Laparoscopy	2	NM
Bae SU,2009 ¹⁵	28	Inferior vena cava, right ovarian vessel	NP	54	1	Yes	Yes	No	Vaginal spotting	0	3.4	TAS + CT	20328	Laparoscopy	2	>24
Fan YY,2011 ¹⁶	31	Near abdominal aorta	NP	63	0	No	No	No	Waist soreness	0	NM	TAS + CT	24145	Conservative fail + NM surgery	1	NM
Ji HJ,2021 ¹⁷	30	The surface of the abdominal aorta and inferior vena cava	NP	52	0	NM	No	No	Right waist and abdominal pain	1	5	CT	25315	Laparoscopy	1	37
Sun BH,2020 ¹⁸	31	Besides the abdominal aorta and above the inferior vena cava	NP	68	0	No	Yes	No	Asymptomatic	0	4.1	TAS + MRI	27414	Laparoscopy	1	21
Hou QX,2021 ¹⁹	29	Near abdominal aorta and left common iliac artery	NP	48	0	NM	No	Yes	Left abdominal pain	0	2	CT	28746	Conservative fail + laparotomy	2	NM
Jia HJ,2011 ²⁰	33		ART	52	0	NM	Yes	No		1	4	TAS	32516	Laparotomy	1	>6

(continued on next page)

Table 1 (continued)

First Author/Year	Age	Site of ectopic pregnancy	Mode of conception	Period of amenorrhea (days)	Times of artificial abortion	Fetal heartbeat	Curetage before surgery	Emergency/shock	Symptoms	Cutting Fallopian tube	Diameter of GS	Diagnosis methods	hCG before treatment (IU/L)	The ultimate treatment	Surgery times	hCG to normal (days)
		Adjacent to the abdominal aorta, the right common iliac artery, and the inferior vena cava							Vaginal spotting							
Veleminisky M,2018 ²¹	38	Above inferior vena cava	NP	53	1	No	No	No	Asymptomatic	0	2.7	TAS	33742	Laparotomy	1	12
Wang FF,2020 ²²	33	Right common iliac vein bifurcation	NP	64	1	No	Yes	No	Vaginal spotting + Waist pain	0	5	TAS	39642	Laparotomy	1	29
Jin CC,2019 ²³	33	Inferior left internal iliac vein	ART	47	0	Yes	No	No	Abdominal pain + Vaginal spotting	2	4	TAS	42822	Laparoscopy	2	NM
Iwama H,2008 ²⁴	31	Adjacent to the aorta and strongly compresses the inferior vena cava	ART	55	0	No	No	Yes	Right upper abdominal pain	2	3.3	TAS + MRI	43409	Conservative fail + laparotomy	2	NM
Lu Q,2019 ²⁵	31	Adjacent to abdominal aorta and inferior vena cava	NP	54	0	Yes	No	No	Abdominal pain + Vaginal spotting	1	3	TAS	47440	Laparoscopy	1	8
Han YF,2020 ²⁶	43	The left side of the abdominal aorta and the beginning of the left common iliac artery	NP	68	1	NM	Yes	No	Asymptomatic	0	3.8	CT	53175	Laparoscopy	1	30
Xiong WJ,2020 ²⁷	28	Next to the left side of the abdominal aorta	NP	60	0	Yes	Yes	No	Vaginal spotting	0	2.7	MRI	54470	Laparoscopy	2	NM
Zhang X,2020 ²⁸	31	The intersection of the abdominal aorta and superior mesenteric artery	NP	44	2	NM	Yes	No	Asymptomatic	1	6	TAS + CT + MRI	57730.9	Laparoscopy	2	14
Ouassour S,2017 ²⁹	35	The left side of the abdominal aorta	NP	52	0	Yes	No	No	Asymptomatic	1	6	TAS	60000	Laparotomy	2	20
Amina MTNR,2019 ³⁰	32	Anterior of abdominal aorta and inferior vena cava	ART	57	NM	Yes	No	No	Vaginal spotting	1	2.5	TAS + MRI	61005	Laparoscopy	1	NM
Wang K,2016 ³¹	29	The left side of the abdominal aorta, below the left renal artery and vein	NP	60	0	Yes	No	No	Left waist pain	NM	11	TAS + MRI	73996	Conservative fail + laparotomy	1	NM
Fu LS,2020 ³²	30	The left side of the abdominal aorta	ART	63	0	Yes	Yes	No	Abdominal pain + Vaginal spotting	1	5	TAS + MRI + CT	89876	Laparotomy	1	>25
Huang XH,2019 ³³	37	The lower left kidney, adjacent to the abdominal aorta	ART	67	1	Yes	No	No	Asymptomatic	2	4.2	TAS + MRI	92079	Conservative successfully	0	120
Zhou X, 2018 ³⁴	29	The left side of the abdominal aorta	NP	60	0	Yes	No	No	Right lower abdominal pain	0	3	TAS	93534	Laparotomy	2	NM
Huang XH,2019 ³³	31	L3 anterior vertebral, between the abdominal aorta and inferior vena cava	NP	66	NM	No	No	No	Asymptomatic	1	4.6	CT	97333	Conservative successfully	0	100
Wen X,2021 ³⁵	28	The left paraaortic region in front of the left kidney	NP	60	NM	Yes	Yes	No	Left lower abdominal pain	0	4	TAS + MRI	99286	Laparoscopy	1	NM

(continued on next page)

Table 1 (continued)

First Author/Year	Age	Site of ectopic pregnancy	Mode of conception	Period of amenorrhea (days)	Times of artificial abortion	Fetal heartbeat	Curetage before surgery	Emergency/shock	Symptoms	Cutting Fallopian tube	Diameter of GS	Diagnosis methods	hCG before treatment (IU/L)	The ultimate treatment	Surgery times	hCG to normal (days)
Wang X,2013 ³⁶	43	Next to inferior vena cava (about 3 cm from the bifurcation of abdominal aorta)	NP	47	NM	NM	Yes	Yes	Abdominal pain + Vaginal spotting	0	NM	Laparotomy Exploration	> 10000	Laparotomy	1	30
Chen Y,2011 ³⁷	34	Under the left kidney, close to the abdominal aorta	ART	50	2	No	Yes	Yes	Left abdominal pain	2	NM	CT	> 1500	Laparotomy	1	NM
Zhou L,2008 ³⁸	38	Adjacent to the abdominal aorta and the inferior vena cava	NP	58	1	No	Yes	No	Abdominal pain	0	3.7	TAS	> 15000	Laparotomy	1	NM
Hu MH,2010 ³⁹	25	In front of the inferior vena cava, between the inferior vena cava and the abdominal aorta	NP	60	7	NM	Yes	No	Right lower abdominal pain + Vaginal spotting	0	4	TAS + CT	52499–2188	Laparotomy	1	> 20
Li L,2019 ⁴⁰	35	The surface of the abdominal aorta, 5 cm above the bifurcation of left and right common iliac arteries	NP	60	NM	NM	No	Yes	Abdominal pain + Vaginal spotting	0	NM	Laparotomy Exploration	58830–1391	Conservative rupture + laparotomy	2	NM
Lotus PC,1977 ⁴¹	30	Near abdominal aorta and left common iliac artery	NP	112	0	NM	Yes	No	Abdominal pain + Vaginal spotting	0	10	TAS	NM	Laparotomy	2	NM
Persson J,2010 ⁴²	33	Distal bifurcation of right external iliac vein	ART	45	0	Yes	No	No	Vaginal spotting	1	2.5	TVS	NM	Da Vinci-S system	3	35
Zhang J, 2019 ⁴³	28	The left side of the abdominal aorta	NP	37	NM	Yes	No	Yes	Lower abdominal pain	1	2.2	TAS	NM	Laparotomy	1	NM
Janie OP, 2018 ⁴⁴	30	Not clear, in the retro-peritoneal hematoma	NP	62	0	NM	No	Yes	Flank + abdominal pain, hypotensive	0	NM	Laparotomy Exploration	40532	Laparotomy	2	28
Munzar Z,2022 ⁴⁵	23	The left side of the aorta above the inferior mesenteric artery	NP	42	0	No	No	Yes	Abdominal pain + Vaginal spotting	1	NM	TAS	12016	Laparotomy	1	> 7
Xu HN, 2022 ⁴⁶	29	On the surface of inferior vena cava and the left side of abdominal aorta	NP	50	1	Yes	No	No	Abdominal pain	0	4.5	TAS + CT	81447	Laparotomy	1	23
Ren JX, 2022 ⁴⁷	30	On the surface of inferior vena cava	NP	47	2	Yes	Yes	No	Asymptomatic	0	2.5	TAS + CT	17351	Laparoscopy	2	20
Anh ND, 2022 ⁴⁸	34	Next to the right common iliac artery	ART	48	0	No	No	No	Asymptomatic	2	2.5	TAS + MRI	36386	Laparotomy	2	28
Tong A, 2022 ⁴⁹	24	On the right side of the abdominal aorta and in front of the inferior vena cava	NP	NM	NM	NM	Yes	No	Asymptomatic	0	3	TAS + CTA	NM	Laparoscopy	2	NM
Yuan J, 2022 ⁵⁰	32	On the right side of the abdominal aorta and in front of the inferior vena cava	ART	57	NM	No	NM	No	Asymptomatic	1	3.5	TAS + MRI	NM	Laparoscopy	1	NM
My TL, 2020 ⁵¹	31	In the left side of the abdominal aorta	ART	57	NM	No	No	Yes	Aute abdominal pain	2	0.5	TAS + CT	20.6	Laparotomy	1	NM
Chukwudi OO, 2010 ⁵²	28	In the right of the abdominal aorta	NP	47	0	NM	No	Yes		0	5.4	Laparotomy Exploration	NM	Laparotomy	2	30

(continued on next page)

Table 1 (continued)

First Author/Year	Age	Site of ectopic pregnancy	Mode of conception	Period of amenorrhea (days)	Times of artificial abortion	Fetal heartbeat	Curettage before surgery	Emergency/shock	Symptoms	Cutting Fallopian tube	Diameter of GS	Diagnosis methods	hCG before treatment (IU/L)	The ultimate treatment	Surgery times	hCG to normal (days)
Yang YZ, 2018 ⁵³	34	In the right lateral abdominal peritoneum region	NP	52	0	NM	No	Yes	Acute abdominal pain	0	2	CT	6803	Laparotomy	1	10
Zhang M, 2017 ⁵⁴	29	In the left side of the abdominal aorta	NP	60	NM	Yes	No	No	pain + Vaginal spotting	NM	4.1	TAS	36312	Laparotomy	1	NM
Shen DS, 2023 ⁵⁵	30	On the surface of inferior vena cava and the left side of abdominal aorta	NP	65	0	NM	Yes	No	Tenderness in the left lower flank	1	3.9	TAS + CT	28257	Laparoscopy	3	17
Liu ZS, 2023 ⁵⁶	27	In the right of the abdominal aorta	ART	57	0	Yes	No	No	Asymptomatic	2	2.5	TAS	18210	Laparoscopy	1	21

Note: NP: Natural pregnancy ART: Assisted reproduction technology GS: Gestational sac hCG: human chorionic gonadotropin NM: Not mentioned. CT: Computed tomography MRI: Magnetic resonance imaging TAS: Transabdominal ultrasound TVS: Transvaginal ultrasound.

reported a tumor diameter of 11 cm, possibly due to a mixed hematoma. Among the ten conservative cases, only three cases had fetal heartbeats. In the case where the pregnancy sac ruptured during conservative treatment, the patient had amenorrhea for 60 days, but there was no fetal heartbeat reported. The use of oral mifepristone led to a decrease in β -hCG levels from 58,830IU/L to 1,391IU/L, after which the rupture occurred.

Among the patients who underwent surgery, five of them experienced bleeding exceeding 1,000 ml, with specific volumes recorded as follows: 1,100 ml, 1,500 ml, 2,200 ml, 2,500 ml, and 4,000 ml, respectively. All of these patients presented with acute abdomen before the operation and subsequently underwent laparotomy. On the other hand, the remaining patients had bleeding \leq 500 ml. It is worth noting that in the past, laparoscopic technology was not as advanced as it is today. Including data from previous cases in the statistics could potentially lead to incorrect conclusions by inaccurately inflating the proportion of open surgeries. To avoid this issue, the study will only consider surgical cases from the year 2000 onwards. After excluding cases with acute abdomen (14 cases), unmentioned surgical methods (1 cases), and those undergoing conservative treatment (2 cases), the most common surgery performed was laparoscopy, accounting for 55.3 % (21/38) of the cases, while laparotomy comprising 42.1 % (16/38) of the cases, followed by Leonardo da Vinci surgery (2.6 %, 1/38) of the cases. There were no reported complications. Out of the 55 cases reviewed in the literature, 9 cases received MTX treatment after surgery, or they were administered oral mifepristone. Additionally, 5 cases showed the presence of lymphoid tissue in the pathology reports.

4. Discussion

The location of REP is rather complex but is generally situated around the posterior aspect of major blood vessels. From an anatomical and surgical perspective, it can be simplistically categorized into two types: pelvic REP and abdominal REP. The former refers to pregnancies located in the retroperitoneum below the iliac arteries and veins, comprising 34.6 % (9/26) of cases. The latter refers to pregnancies occurring within the retroperitoneum surrounding the iliac arteries, veins, abdominal aorta, and inferior vena cava, constituting 65.4 % (17/26) of cases.⁵⁷ The previous literature review focused on retroperitoneal pregnancy in general, while this article represents the first study exclusively addressing the unique and high-risk subset of retroperitoneal "para-aortic" ectopic pregnancies (a notably large blood vessel). This study includes literature from both Chinese and English sources, encompassing a total of 55 cases, enhancing the generalizability of the derived data.

This review reveals the characteristics of RPEP: Extrauterine pregnancy adjacent to blood vessels is commonly found in locations such as the abdominal aorta, inferior vena cava, and iliac vessels. Ectopic pregnancy represents a potentially life-threatening diagnosis, in the case of rupture, and timely intervention allows for surgical excision.⁵⁸ Nevertheless, based on the collected data from RPEP patients, while some experienced acute abdominal symptoms and rupture of the pregnancy sac, none of them compromised the integrity of the large blood vessels surrounding RPEP. This may be attributed to the thicker walls of these major blood vessels, resulting in an earlier diagnosis compared to the time when the pregnancy sac invades major blood vessels and causes rupture. Nevertheless, due to their proximity to major blood vessels within the abdominal cavity, surgical intervention in RPEP carries higher sever bleeding risks compared to other locations of ectopic pregnancy. The later the diagnosis, the higher the treatment risk associated with RPEP; therefore, it is imperative to widely disseminate the concept of RPEP and related diagnostic and treatment strategies, enhancing the diagnostic efficiency of medical personnel.

The mechanism of embryo migration to the retroperitoneal space is indeed intriguing. Several pathogenesis pathways have been proposed to explain this phenomenon: (1) Transvascular Transfer: During implantation, fertilized egg cells may detach and enter ruptured lymphatic

Table 2
Data of general information, clinical manifestation, diagnosis and treatment.

	Information	Number/ ratio	
General information	Age (y) (Range)	19–43	
	Fallopian tube surgery history n (%)	28 (50.9)	
	Artificial abortion history n (%)	12 (21.8)	
	IVF-ET n (%)	17 (30.9)	
	Gestational days(d) (Range)	37–112	
Clinical manifestations	Endometriosis n (%)	2 (3.6)	
	Abdominal pain n (%)	24 (43.6)	
	Vaginal bleeding n (%)	20 (36.4)	
	Waist pain n (%)	6 (10.9)	
	Abdominal pain and vaginal bleeding n (%)	14 (25.5)	
	Asymptomatic n (%)	18 (32.7)	
	Severe symptoms or unstable vital signs n (%)	14 (25.5)	
	Diagnosis	Examinations	Transabdominal ultrasound n (%)
Abdominal CT n (%)			8 (14.5)
Abdominal ultrasound with CT or MRI n (%)			20 (36.4)
β-hCG	Surgical exploration n (%)	7 (12.7)	
	Plasma β-hCG (IU/L) (Range)	20.6–99286	
	The P ₅₀ of the plasma β-hCG (IU/L)	28257	
	β-hCG between 0 and 5000 (IU/L) n (%)	7 (12.7)	
	β-hCG > 5000(IU/L) n (%)	42 (76.4)	
Diameter of sac	Diameter (cm) (Range)	0.5–11	
	Diameter between 0 and 3.5 cm n (%)	25 (45.5)	
	Diameter > 3.5 cm n (%)	24 (43.6)	
The sac ruptured	With fetal heartbeat n (%)	3 (13.6)	
	Without fetal heartbeat n (%)	3 (27.3)	
Treatment	Laparoscopy n (%)	21 (55.3)	
	Laparotomy n (%)	16 (42.1)	
	Da Vinci-S system n (%)	1 (2.6)	
	Conservative success n (%)	2 (20)	
	hCG normalization time after surgery (d) (Range)	3–37	

Note: IVF-ET: in vitro fertilization-embryo transfer CT: Computed tomography. hCG: human chorionic gonadotropin MRI: Magnetic resonance imaging.

capillaries, eventually migrating to the retroperitoneal space. (2) Implantation transfer: In this scenario, the embryo initially implants on the peritoneal surface following a ruptured or aborted tubal pregnancy. It then invades the retroperitoneal space through trophoblastic infiltration of the peritoneum. (3) Fistula transfer: After undergoing salpingectomy, the broken end of the fallopian tube may connect with the retroperitoneum. The embryo can then implant through the fistula or

Table 3
Distinction between pelvic RPEP and abdominal RPEP.

	Adjacent to abdominal aorta, inferior vena cava (n=41)	Adjacent to iliac vessels (n=14)	P-value/ χ ²
Severe symptoms or unstable vital signs n (%)	10(24.4)	4(28.6)	0.096
Diameter of sac/cm (x̄ ±s)	3.81 ± 1.74	3.77 ± 2.39	0.441
hCG before surgery (IU/L) (x̄ ±s)	40445 ± 30081	18202 ± 16681	0.027
Times of surgery (x̄ ±s)	1.34 ± 0.62	1.57 ± 0.65	0.277
hCG normalization time after surgery/d (x̄ ±s)	19.29 ± 8.69	16.73 ± 11.1	0.134

Note:Among the continuous data, only the hCG normalization time after surgery followed a normal distribution. Abdominal RPEP: the sac adjacent to abdominal aorta, inferior vena cava. Pelvic RPEP: the sac adjacent to iliac vessels.

Table 4
Distinction between RPEP and Common ectopic pregnancy.

	RPEP	Common EP
Site of ectopic pregnancy	Adjacent to blood vessels: abdominal aorta, inferior vena cava, iliac vessels	Fallopian tubes, uterine horns, ovaries, cervix, etc
Medical history	History of ART, uterine cavity procedures, endometriosis, and tubal surgeries	History of tubal surgery
Symptoms	Abdominal pain, vaginal bleeding, lower back pain	Abdominal pain, vaginal bleeding
Examinations	Abdominal ultrasound, CT, MRI	Transvaginal ultrasound
Severe bleeding risk	High	Low
Preoperative special preparations	Placement of a balloon for hemostasis within major blood vessels, multidisciplinary collaboration	Nothing specific
Treatment	Laparoscopy, laparotomy, conservative treatment	Laparoscopy, laparotomy, conservative treatment
Operator's requirements	The requirements are high, and familiarity with the structure behind the peritoneum is essential	The requirements are low.

Note:RPEP: retroperitoneal para-aortic ectopic pregnancy; EP: ectopic pregnancy.

peritoneal defect. Among the 55 cases identified in the literature, a significant proportion of patients (50.9 %, 28/55) had a history of salpingectomy. This suggests that salpingectomy may be one of the risk factors for retroperitoneal ectopic pregnancies. (4) The fertilized ovum implant on superficial endometriosis tissue, followed by its movement towards vascularized retroperitoneal structures through trophoblastic invasion.⁵⁹ It suggests that endometriosis tissue present within the fallopian tube provides a uterine-like environment where the fertilized ovum can successfully implant.⁶⁰

As for RPEP, we believe that the likelihood of transvascular transfer is higher, and the reasons for this are as follows: Some reported cases have shown the presence of lymphatic vessels in the resected pregnancy tissue.^{21,42,47} Liang et al.⁵ utilized CT reconstruction techniques to observe typical signs of inflammatory responses along the left gonadal vessels, suggesting obstructed lymphatics caused by embryo migration. Vascular metastasis, often observed in diseases involving cell nourishment, typically terminates in lung tissues. Indeed, lymphatic metastasis, as observed in conditions like endometrial cancer and others, tends to spread to the lymph nodes around the aorta and portal vein in the liver.⁶¹ In terms of postoperative pathology, the presence of lymphoid tissue in 5 cases out of 53 (excluding the 2 conservative cases) is noteworthy.

Based on previous reports, we conducted the distinction between RPEP and common ectopic pregnancy as Table 4. It appears that patients with history of artificial abortion, embryo transfer, salpingectomy, and uterine cavity operation, accounted for 65.5 % (36/55) of the cases. If a patient has these risk factors, and a normal location cannot identify the pregnancy sac during initial examination, RPEP should be considered as a potential diagnosis. In 12.7 % (7/55) of cases, the absence of embryo detection through vaginal ultrasound and uterine curettage led to exploratory laparotomy to locate the ectopic pregnancy. However, due to the partial concealment of the gestational sac, some cases concluded the exploratory surgery without identifying the embryo's location, resulting in missed diagnoses and unnecessary medical interventions. As Table 4, transabdominal ultrasound (TAS) serves as the primary method for diagnosing RPEP. TAS offers the advantage of being both economical and convenient, allowing for a preliminary localization of the ectopic pregnancy sac. If needed, abdominal CT or MRI examinations can be pursued. In comparison, MRI provides higher resolution images of soft tissues and multi-directional imaging, facilitating the evaluation of the relationship between the placental implant site and surrounding tissues.⁶² Physicians

should meticulously report the distance and boundary between the pregnancy sac and the surrounding vessels to guide the operative procedure.

Conservative management, interventional therapy, and surgery are all viable treatment options for RPEP. Conservative treatment is considered appropriate for patients who do not exhibit any of the following criteria: significant pain, an adnexal mass of 35 mm or larger, a fetal heartbeat visible on an ultrasound scan, serum hCG level of 5000 IU/L or more.⁶³ Conservative management of RPEP involves imaging-guided intracapsular injection of MTX or intramuscular injection of MTX. This approach is chosen when the pregnancy sac is closely adjacent to large vessels, making surgical intervention risky. Interventional therapy can also be considered in such cases. However, conservative management carries the risk of persistent ectopic pregnancy, and there is a possibility of trophoblast erosion into the celiac vessels, which can lead to bleeding and shock. Therefore, close monitoring and follow-up are necessary to assess the effectiveness of the treatment.³¹ Indeed, MTX can be utilized as an adjunctive treatment to consolidate the therapeutic effect in cases where there is still residue after surgical resection of RPEP. However, for the majority of RPEPs, surgical treatment remains the primary choice, and it includes both laparotomy and laparoscopy. Laparotomy is preferred when patients present with unstable vital signs, as it allows for quicker access and intervention during emergency situations. Laparoscopy offers several advantages, such as a clear vision field and effective hemostasis, making it an increasingly mainstream approach for RPEP surgery.

Once RPEP is diagnosed, adequate preoperative preparations should be made, including the improvement of intraoperative hemostasis equipment. For example, if preoperative auxiliary examination indicates that the pregnancy sac has invaded deep blood vessels and there is a high risk of bleeding during surgery, a hemostatic balloon can be placed in the abdominal blood vessels to prevent massive intraoperative bleeding. The surgical excision of ectopic pregnancy adjacent to major blood vessels is similar to the lymph node clearance in gynecological malignancies. Therefore, it is advisable for the surgeon performing the RPEP procedure to be a gynecological oncology specialist or an expert familiar with retroperitoneal structures. Regular monitoring the patient's plasma β -hCG levels should occur once a week after the operation for RPEP. For patients who undergo conservative treatment, more frequent reexamination is necessary, with β -hCG levels checked every 2–3 days until the plasma β -hCG becomes negative twice.⁶⁴ As illustrated in Table 3, The time for postoperative hCG to return to normal did not show a significant difference, whether the pregnancy sac was located around the abdominal aorta and inferior vena cava or near the iliac vessels. Persistent or rising levels of β -hCG after treatment indicate that the trophoblast is still active and that further intervention is required.³¹

5. Limitations

There is a lack of data supporting a direct comparison between the risks of RPEP and non-retroperitoneal ectopic pregnancy, particularly in terms of factors such as the incidence of acute abdominal symptoms, intraoperative bleeding volume, and mortality rates. Therefore, it is not possible to accurately compare the risks of the two types. Moreover, the data extracted solely from individual cases may suffer from publication bias, such as fewer reported cases of RPEP that had a typical and uncomplicated course of treatment. Therefore, this article solely describes diagnostic and treatment-related data pertaining to RPEP.

6. Conclusions

When discussing symptoms, there isn't much difference between RPEP and general ectopic pregnancy. The outcomes of pregnancies (eg. Severe symptoms or unstable vital signs, hCG normalization time after surgery) in different major vascular locations do not show significant differences. However, there is a higher risk of severe bleeding in RPEP,

necessitating more careful differential examinations. Additional imaging with TAS, CT, or MRI expanding the scope of the scan, may significantly expedite diagnosis and treatment. By promoting early diagnosis and appropriate referral, healthcare providers can optimize patient outcomes and improve the overall management of RPEP.

Author contributions

RJ proposed the concept and designed the study, then collected the data and wrote the manuscript. HH performed critical revision of the manuscript. All authors provided inputs for the manuscript.

Conflicts of interest

The authors declare that they have no conflict of interest.

Funding

This research was supported by the cooperative supported project of the People's Hospital of Peking University (Project:2119000364).

Appendix A. Supplementary data

Supplementary data to this article can be found online at <https://doi.org/10.1016/j.gocm.2023.10.004>.

References

- Bouyer J, Coste J, Fernandez H, et al. Sites of ectopic pregnancy: a 10 year population-based study of 1800 cases. *Hum Reprod.* 2002;17(12):3224–3230. <https://doi.org/10.1093/humrep/17.12.3224>.
- Atrash HK, Friede A, Hogue CJ. Abdominal pregnancy in the United States: frequency and maternal mortality. *Obstet Gynecol.* 1987;69(3 Pt 1):333–337.
- Tan QH, Gao M. Abdominal ectopic pregnancy: a case report. *J Baotou Med Coll.* 2016;32(3):144–145. <https://doi.org/10.16833/j.cnki.jbmc.2016.03.087>.
- Lin JX, Liu Q, Ju Y, et al. Primary obturator foramen pregnancy: a case report and review of literature. *Chin Med J (Engl).* 2008;121(14):1328–1330. <https://doi.org/10.1186/1741-7015-6-20>.
- Liang C, Li X, Zhao B, et al. Demonstration of the route of embryo migration in retroperitoneal ectopic pregnancy using contrast-enhanced computed tomography. *J Obstet Gynaecol Res.* 2014;40(3):849–852. <https://doi.org/10.1111/jog.12233>.
- Sun N, Wang W, Hou XT, et al. Retroperitoneal ectopic pregnancy: a case report. *Chin J Med Imag.* 2021;29(11):1139–1140. <https://doi.org/10.3969/j.issn.1005-5185.2021.11.019>.
- Li LG, Xia M, Liu JX, et al. Retroperitoneal ectopic pregnancy: a case report. *Chin J Obstet Gynecol.* 2018;53(5):341. <https://doi.org/10.3760/cma.j.issn.0529-567x.2018.05.015>.
- Reid F, Steel M. An exceptionally rare ectopic pregnancy. *BJOG.* 2003;110(2):222–223. [https://doi.org/10.1016/S1470-0328\(02\)01672-5](https://doi.org/10.1016/S1470-0328(02)01672-5).
- Wu XW, Zhao Z, Xu W, et al. Intraoperative ultrasound assisted surgery for rare retroperitoneal ectopic pregnancy: a case report. *Med J Chin People's Armed Police Forces.* 2021;32(9):802–803. <https://doi.org/10.14010/j.cnki.wjyx.2021.09.017>.
- Bian J, Li BQ, Wang ZM. Retroperitoneal ectopic pregnancy: a case report. *Chin J Pract Obstetrics Gynecol.* 2019;35(8):954–956. <https://doi.org/10.19538/j.fk2019080126>.
- Qiu JN, Luo CY, Huang XH, et al. Ectopic pregnancy on the surface of retroperitoneal inferior vena cava: a case report and literature review. *Nan Jing Med Univ.* 2016;36(5):629–631. <https://doi.org/10.7655/NYDXBNS20160525>.
- Liu Y, Jing CL, Li YX. Retroperitoneal para-aortic ectopic pregnancy: a case report and literature review. *Chin J Pract Obstetrics Gynecol.* 2015;31(7):687–688. <https://doi.org/10.7504/fk2015060128>.
- Lang TY, Ji M, Zhao J, et al. Retroperitoneal ectopic pregnancy: a case report. *J Pract Obstetrics Gynecol.* 2021;37(11):879–880. <https://doi.org/10.3760/cma.j.cmc.2022.e04784>.
- Jing WY, Yue LX, Cai ZQ. Ultrasonic diagnosis of retroperitoneal gestation: a case report. *J Ultras Med.* 2019;21(9):718. <https://doi.org/10.16245/j.cnki.issn1008-6978.2019.09.031>.
- Bae SU, Kim CN, Kim KH, et al. Laparoscopic treatment of early retroperitoneal abdominal pregnancy implanted on inferior vena cava. *Surg Laparosc Endosc Percutan Tech.* 2009;19(4):e156–e158. <https://doi.org/10.1097/SLE.0b013e3181ab91b0>.
- Fan YY, Chen WB, Wang L, et al. Retroperitoneal paraaortic pregnancy: a case report [C]. In: *2011 Annual Conference of Obstetrics and Gynecology in Zhejiang Province and Study Class of "new Progress in Clinical Research of Common Diseases in Obstetrics and Gynecology."* 2011:189. Hangzhou, Zhejiang, China.
- Ji HJ, Gao JC. Laparoscopic treatment of retroperitoneal pregnancy: a case report. *Chin J Minim Invas Surg.* 2021;21(7):670–672. <https://doi.org/10.3969/j.issn.1009-6604.2021.07.020>.

18. Sun BH, Yu YQ, Sang HA, et al. Retroperitoneal ectopic pregnancy: a case report and literature review. *Prog Obstet Gynecol.* 2020;29(2):157–158. <https://doi.org/10.13283/j.cnki.xdfckjz.2020.02.019>.
19. Hou Q, Xin L, Jian L, et al. Retroperitoneal ectopic pregnancy: a case report and literature review. *J Obstet Gynaecol Res.* 2021;47(3):1186–1190. <https://doi.org/10.1111/jog.14669>.
20. Jia HJ, Zeng WX, Wang QY, et al. Primary retroperitoneal pregnancy after IVF-ET: a case report and literature review. *Med Inf.* 2011;24(7):4788. <https://doi.org/10.3969/j.issn.1006-1959.2011.07.728>.
21. Veleminsky M, Stepanek O, Koznar P, et al. A rare case of ectopic pregnancy - retroperitoneal ectopic pregnancy. *Neuroendocrinol Lett.* 2018;39(3):156–159.
22. Wang FF, Liu EL, Wang YF, et al. Rare retroperitoneal pregnancy with mild anemia: a case report. *Chin J Clin Obstetrics Gyn Ecol.* 2020;21(5):543–544. <https://doi.org/10.13390/j.issn.1672-1861.2020.05.038>.
23. Jin CC, Zhou P, Chu HT, et al. Retroperitoneal ectopic pregnancy after in vitro fertilization and embryo transfer: case report. *Chin J Med Imaging Tech.* 2019;35(9):1438. <https://doi.org/10.13929/j.1003-3289.201811128>.
24. Iwama H, Tsutsumi S, Igarashi H, et al. A case of retroperitoneal ectopic pregnancy following IVF-ET in a patient with previous bilateral salpingectomy. *Am J Perinatol.* 2008;25(1):33–36. <https://doi.org/10.1055/s-2007-1004829>.
25. Lu Q, Zhang Z, Zhang Z. Laparoscopic management of retroperitoneal ectopic pregnancy. *J Minim Invasive Gynecol.* 2019;26(3):405–406. <https://doi.org/10.1016/j.jmig.2018.07.007>.
26. Han YF, Hou P, Liu YS, et al. Retroperitoneal para-aortic ectopic pregnancy: a case report and literature review. *Chin J Family Plann Gynecotokol.* 2020;12(4):92–93. <https://doi.org/10.3969/j.issn.1674-4020.2020.04.24>.
27. Xiong WJ, Wu Q, Liu HP, et al. MRI findings of retroperitoneal ectopic pregnancy: a case report. *Natl Med J Chin.* 2020;21(16):1676–1677. <https://doi.org/10.3760/cma.j.cn112137-20191112-02461>.
28. Zhang X, Xu S, Tong JY. Hysteroscopy combined with laparoscopy in the treatment of primary retroperitoneal pregnancy: a case report. *J Laparoscopic Surg.* 2020;25(4):319–320. <https://doi.org/10.13499/j.cnki.fqjwkwz.2020.04.319>.
29. Ouassour S, Filali AA, Raiss M, et al. Retroperitoneal ectopic pregnancy: diagnosis and therapeutic challenges. *Case Rep Surg.* 2017;2017:9871865. <https://doi.org/10.1155/2017/9871865>.
30. Amina MN, Xie H, Zeng F, et al. Primary retroperitoneal pregnancy: a case report. *J Mol Imag.* 2019;42(1):138–140. <https://doi.org/10.12122/j.issn.1674-4500.2019.01.32>.
31. Wang K, Zhu GH, Qin LL, et al. Clinical diagnosis and treatment of abdominal pregnancy: a report of 3 cases. *Prog Obstet Gynecol.* 2016;25(12):939–941. <https://doi.org/10.13283/j.cnki.xdfckjz.2016.12.017>.
32. Fu LS, Zhao HY. Retroperitoneal pregnancy after in vitro fertilization embryo transfer: a case report. *Prog Obstet Gynecol.* 2020;29(3):240. <https://doi.org/10.13283/j.cnki.xdfckjz.2020.03.020>.
33. Huang X, Zhong R, Tan X, et al. Conservative management of retroperitoneal ectopic pregnancy by computed tomographic-guided methotrexate injection in the gestational sac: 2 case reports and literature review. *J Minim Invasive Gynecol.* 2019;26(6):1187–1192. <https://doi.org/10.1016/j.jmig.2018.12.016>.
34. Zhou X, Chen FQ. *Ultrasonic Diagnosis of Retroperitoneal Ectopic Pregnancy: a Case report[C]//The 7th National Conference on Ultrasound Medicine in Obstetrics and Gynecology of China Society of Ultrasound Medical Engineering.* Henan, China: Zhengzhou; 2018:60–61. <https://doi.org/10.26914/c.cnkihy.2018.001090>.
35. Wen X, Yan X, Zhang Q, et al. Retroperitoneal ectopic pregnancy: a case report. *J Minim Invasive Gynecol.* 2021;28(9):1662–1665. <https://doi.org/10.1016/j.jmig.2021.05.008>.
36. Wang X, Yu WH. Retroperitoneal ectopic pregnancy: a case report. *Chin Mod Med.* 2013;20(10):143. <https://doi.org/10.3969/j.issn.1674-4721.2013.10.070>.
37. Chen Y. Retroperitoneal ectopic pregnancy: a case report. *Chin J Pract Obstetrics GynEcol.* 2011;27(11):876.
38. Zhou L, Zhang Q, Tong JY. Ultrasonic diagnosis of retroperitoneal ectopic pregnancy: a case report. *J Ultras Clin Med.* 2008;10(12):851. <https://doi.org/10.16245/j.cnki.issn1008-6978.2008.12.018>.
39. Hu MH, Weng YY. Retroperitoneal ectopic pregnancy: a case report. *Chin J Obstet Gynecol.* 2010;11:879. <https://doi.org/10.3760/cma.j.issn.0529-567x.2010.11.021>.
40. Li L, Peng LX. Primary ectopic pregnancy of abdominal aorta: a case report. *J Pract Obstetrics GynEcol.* 2019;35(2):159–160.
41. Sotus PC. Retroperitoneal ectopic pregnancy: a case report. *JAMA.* 1977;238(13):1363–1364. <https://doi.org/10.1001/jama.1977.03280140041007>.
42. Persson J, Reynisson P, Måsbäck A, et al. Histopathology indicates lymphatic spread of a pelvic retroperitoneal ectopic pregnancy removed by robot-assisted laparoscopy with temporary occlusion of the blood supply. *Acta Obstet Gynecol Scand.* 2010;89(6):835–839. <https://doi.org/10.3109/00016341003623779>.
43. Zhang J, Li QF. Retroperitoneal ectopic pregnancy: a case report. *World Latest Med Inf.* 2019;19(57):257. <https://doi.org/10.19613/j.cnki.1671-3141.2019.57.163>.
44. Pak JO, Durfee JK, Pedro L, et al. Retroperitoneal ectopic pregnancy. *Obstet Gynecol.* 2018;132(6):1491–1493. <https://doi.org/10.1097/aog.0000000000002965>.
45. Munzar Z, Afridi KD, Amin F, et al. Retroperitoneal ectopic pregnancy presenting as a massive retroperitoneal hematoma. *J Coll Physicians Surg Pak.* 2022;32(3):415–416. <https://doi.org/10.29271/jcpsp.2022.03.415>.
46. Xu H, Cheng D, Yang Q, et al. Multidisciplinary treatment of retroperitoneal ectopic pregnancy: a case report and literature review. *BMC Pregnancy Childbirth.* 2022;22(1):472. <https://doi.org/10.1186/s12884-022-04799-5>.
47. Ren J, Shi J, Zhang G, et al. A retroperitoneal perivascular ectopic pregnancy case: diagnosis and possible lymphatic migration. *J Minim Invasive Gynecol.* 2022;29(11):1203–1207. <https://doi.org/10.1016/j.jmig.2022.06.019>.
48. Anh ND, Hai NX, Ha NT, et al. Retroperitoneal ectopic pregnancy after in vitro fertilization: a case report of a patient with bilateral salpingectomy. *Radiol Case Rep.* 2022;17(3):721–724. <https://doi.org/10.1016/j.radcr.2021.12.011>.
49. Tong A, Pu Y, Ye J, et al. Complete resection of retroperitoneal ectopic pregnancy adherent to the inferior vena cava by laparoscopy. *J Minim Invasive Gynecol.* 2022;29(7):810–811. <https://doi.org/10.1016/j.jmig.2022.03.009>.
50. Yuan J, Xie H, Chen M, et al. A case report of retroperitoneal ectopic pregnancy with lymphatic migration after in vitro fertilization-embryo transfer: an explanation to embryo distant migration. *Fertil Steril.* 2022;118(3):598–600. <https://doi.org/10.1016/j.fertnstert.2022.05.034>.
51. Le MT, Huynh MH, Cao CH, et al. Retroperitoneal ectopic pregnancy after in vitro fertilization/embryo transfer in patient with previous bilateral salpingectomy: a case report. *Int J Gynaecol Obstet.* 2020;150(3):418–419. <https://doi.org/10.1002/ijgo.13136>.
52. Okorie CO. Retroperitoneal ectopic pregnancy: is there any place for non-surgical treatment with methotrexate? *J Obstet Gynaecol Res.* 2010;36(5):1133–1136. <https://doi.org/10.1111/j.1447-0756.2010.01270.x>.
53. Yang Y, Liu Z, Song L, et al. Diagnosis and surgical therapy of the retroperitoneal ectopic pregnancy: a case report. *Int J Surg Case Rep.* 2018;49:21–24. <https://doi.org/10.1016/j.ijscr.2018.05.027>.
54. Zhang M, Qin LL. A case of retroperitoneal para-aortic ectopic pregnancy detected by sonography. *J Clin Ultrasound.* 2018;46(6):412–414. <https://doi.org/10.1002/jcu.22554>.
55. Dongsheng S, Chenghao W, Miaobo C, et al. Laparoscopic surgery combined with methotrexate in the treatment of retroperitoneal ectopic pregnancy: a case report. *J Tongji Univ.* 2023;44(2):301–304. <https://doi.org/10.12289/j.issn.1008-0392.22378>.
56. Liu Z, Jing C. A case report of retroperitoneal ectopic pregnancy after in vitro fertilization-embryo transfer and literature review. *Int J Womens Health.* 2023;15:679–693. <https://doi.org/10.2147/ijwh.S408319>.
57. Ouyang Z, Wei S, Wu J, et al. Retroperitoneal ectopic pregnancy: a literature review of reported cases. *Eur J Obstet Gynecol Reprod Biol.* 2021;259:113–118. <https://doi.org/10.1016/j.ejogrb.2021.02.014>.
58. Petrini A, Spandorfer S. Recurrent ectopic pregnancy: current perspectives. *Int J Womens Health.* 2020;12:597–600. <https://doi.org/10.2147/ijwh.S223909>.
59. Di Lorenzo G, Romano F, Mirenda G, et al. "Nerve-sparing" laparoscopic treatment of parametrial ectopic pregnancy. *Fertil Steril.* 2021;116(4):1197–1199. <https://doi.org/10.1016/j.fertnstert.2021.05.106>.
60. Coyne K, Flyckt R, Findley J. A management algorithm and proposed pathogenesis for retroperitoneal ectopic pregnancies. *Fertil Steril.* 2021;116(4):1200–1201. <https://doi.org/10.1016/j.fertnstert.2021.08.012>.
61. Yabushita H, Shimazu M, Yamada H, et al. Occult lymph node metastases detected by cytokeratin immunohistochemistry predict recurrence in node-negative endometrial cancer. *Gynecol Oncol.* 2001;80(2):139–144. <https://doi.org/10.1006/gyno.2000.6067>.
62. Hu S, Song Q, Chen K, et al. Contrast-enhanced multiphase CT and MRI of primary hepatic pregnancy: a case report and literature review. *Abdom Imag.* 2014;39(4):731–735. <https://doi.org/10.1007/s00261-014-0101-5>.
63. Diagnosis and management of ectopic pregnancy: green-top guideline No. 21. *BJOG.* 2016 Dec, 123(13):e15–e55. doi: 10.1111/1471-0528.14189.
64. Diagnosis and management of ectopic pregnancy: green-top guideline No. 21. *Bjog.* 2016;123(13):e15–e55. <https://doi.org/10.1111/1471-0528.14189>.