

Methodology

Using a needle for sacrospinous ligament fixation for pelvic organ prolapse based on the Miyazaki technique



Ilnur Irekovich Musin^{a,*}, Alfiya Galimovna Yashchuk^a, Valentin Nikolaevich Pavlov^a, Jianliu Wang^b, Xiuli Sun^b, Raisa Arkadevna Naftulovich^a, Elena Mikhailovna Popova^a

^a Federal State Budgetary Educational Institution of Higher Education Bashkir State Medical University of the Ministry of Health of the Russian Federation, Lenina 3, Ufa, Republic of Bashkortostan, 450008, Russia

^b Department of Obstetrics and Gynecology, Peking University People's Hospital, 11th Xizhimen South Street, Xicheng District, Beijing, 100044, China

ARTICLE INFO

Keywords:

Pelvic organ prolapse
Sacrospinous ligament fixation
Sacrocolpopexy
Pelvic surgery

ABSTRACT

Background: Approximately 7% of all women will require surgery to correct pelvic organ prolapse during their lives. Of these, approximately 10%–13% will require another operation within 5 years due to recurrence of the disease. Increases in life expectancy and elderly individuals with estrogen deficiencies will mean higher rates of pelvic organ prolapse, significantly reducing the quality of life for millions of people. This study introduces technologies that can help treat pelvic prolapse while reducing the rate of recurrence.

Methods: This paper outlines how to properly perform sacrospinous ligament fixation using the Miyazaki technique.

Results: A needle was used to successfully perform a sacrospinous ligament fixation using Miyazaki's technique. **Conclusions:** Considering the Food and Drug Administration's 2019 decision to permit surgeries with native tissue, this method can be used with sacrospinous ligament fixation as the primary treatment option for pelvic organ prolapse.

1. Introduction

Hysterectomies are one of the most commonly performed surgical procedures. Approximately 7% of all women will require surgery to correct pelvic organ prolapse during their lives. Of these, approximately 10%–13% will require another operation within 5 years due to recurrence of the disease; 29% will undergo more than one corrective operations.¹ According to Friedman et al., from 1995 to 2017, there was an average recurrence of 36% when reconstruction was performed using native tissues. However, if the hysterectomy was performed to treat pelvic prolapse, the risk of recurrence increased significantly.^{2,3} There are currently more than 500 methods of surgically treating pelvic organ prolapse. Surgery is the only effective method of treating genital prolapse, however, the recurrence rate of the disease after correction can reach 33%–40%.⁴ According to the Federal State Statistics Service, a 0.7-year

increase in the life expectancy of women was observed in 2019 compared with 2018; the average life expectancy now exceeds 78.5 years old.⁵ The proportion of elderly individuals in developing countries is expected to increase from 9% of the population (605 million) in 2009 to 20% (2 billion) in 2050.⁶ From 2000 to 2050, the proportion of the world's population over the age of 60 will increase from approximately 11%–22%.⁷ As life expectancy increases, women will, on average, live more than two decades after menopause. This estrogen deficiency can lead to the prolapse of pelvic organs and significantly reduce the quality of life.⁸ As such, there is a need for technologies to treat and reduce the recurrence rate of pelvic organ prolapse.

The primary surgical methods used to correct pelvic prolapse are laparoscopy, laparotomy, vaginal surgery, and robot-assisted sacrocolpopexy.⁹ Operations requiring abdominal access require inpatient treatment, long-term rehabilitation, and are expensive, while

* Corresponding author. Bashkir State Medical University: Baskirskij gosudarstvennyj medicinskij universitet, Russia.

E-mail address: ilnur-musin@yandex.ru (I.I. Musin).



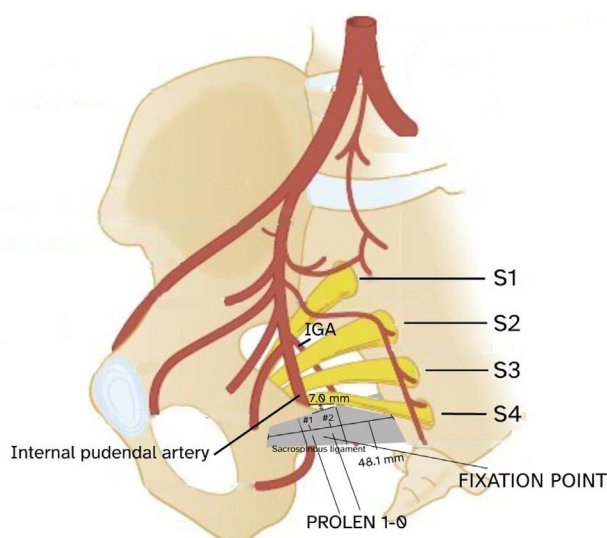


Fig. 1. Identification of the right coccygeal-sacrospinous ligament (diagram).

laparoscopic surgeries have a much shorter rehabilitation period.¹⁰ Laparoscopically fixing the implant to the sacrospinal ligaments is not always technically feasible, particularly in elderly and senile patients.⁹

One method for prevention and correction of pelvic organ prolapse entails fixation to the sacrospinal ligament, per the Miyazaki technique.¹¹ Vaginal access allows fixation to the sacrospinous ligament and promotes restoration of apical prolapse since the vaginal stump can be affixed to the right sacrospinous ligament. sacrospinous ligament fixation is the best option if the patient has contraindications, refuses to use a mesh prosthesis, or has a gastrointestinal tract disease.^{12,13} Surgically treating the enterocele by vaginal access requires forming a bridge to the vagina from a prolene graft. In this case, the distal end of the graft is attached with non-absorbent sutures to the right sacrospinous ligament. A vaginal stump made of non-absorbent suture material is fixed to the proximal end.¹⁴ However, certain patients might not be able to receive this treatment if there are significant changes to the vaginal axis from previous operations.

Pelvic surgeries, including apical prolapse correction, aim to restore the anatomy of the vagina. This leads to restoration of bladder and intestine functioning. According to a survey conducted by the International Urogynecological Association (IUGA), 78% of respondents indicated that sacrospinal fixation was their primary choice for correcting apical prolapse.¹⁵ However, this method is now less popular due to the rise of laparoscopic and robot-assisted surgeries. Sacrospinous fixation is cheaper, can be performed quickly, and requires a shorter hospital stay. According to Maher C et al.,¹⁶ there were higher risks of developing cystoceles after sacrospinal fixation in patients who did not undergo correction. Sacrospinous fixation is associated with a lower risk of relapse and dyspareunia, while vaginal meshes are used only in difficult cases and relapses in older women. Using vaginal mesh prostheses to treat pelvic organ prolapse and urinary incontinence is currently being debated by experts. While mesh implants have been pulled from the market in many countries, they are still used in most countries in continental Europe, Asia, and South America.¹⁷

The length of the sacrospinous ligament varies from 30.0 to 65.4 mm, while the average length is 48.1 mm with no significant difference on either side. In 67% of cases, the pudendal nerve originates above the lateral third of the sacrospinous ligament; in 15% of cases, the S3 nerve root runs parallel to the upper border of the sacrospinous ligament; in 85% of cases, the distance between the nerve and the upper edge of the sacrospinous ligament is 7.0 mm. The inferior gluteal artery passes through the greater sciatic foramen between the roots S2 and S3, while

the internal gluteal artery extends above the ischium (Fig. 1).¹⁸ The inferior gluteal artery and the internal genital artery are typically far from the suture site but can pass close to the ligament.

According to Karram MM et al., a common complication of fixation is pudendal nerve damage.¹⁹ Suturing is not recommended in the medial third of the sacrospinous ligament, since that is where the S4 root is typically located. After surgery, the patient can develop de novo perineal pain, genital numbness, and urinary and fecal incontinence.¹⁸ The middle segment of the sacrospinous ligament has the lowest incidence of nerve and arterial damage and is less likely to trap a nerve or damage an artery. With an average length of 48.1 mm, it is located approximately 16.0–32.0 mm from the ischial tubercle. The midsection of the ligament is closer to the rectum, meaning that the rectum must be protected before suturing.

2. Materials and methods

A typical needle used for sacrospinous ligament fixation consists of an arcuate curved working part. At the pointed end, there is a hole for a thread to puncture the tissue. The design of the needle also contains an elongated handle for threading the rod. The design of the needle is highly efficient and can significantly reduce certain complications. This needle is reliable and can be used in pelvic surgery.

The patient is placed in the lithotomy position, while the sacrospinous ligament is accessed by making an incision along the posterior wall of the vagina. The right pararectal space in the area of localization of the sciatic spine is bluntly and sharply dissected. The right coccygeal-sacrospinous ligament is then identified, which is located to the side of the rectum and above the pubococcygeal muscle. The ligament is exposed using a pair of Breisky-Navratil retractors. The first retractor is located in the anterior, while the second is used to medially retract the rectum from the ligament and the third retractor is located below (Figs. 1 and 2). Due to the location of the ligament, the relatively narrow space for dissection and the proximity to the rectum, the working part of the needle has a rod with a circular cross-section and a pointed end with a hole for the thread. The working part sits at a 30° angle from the handle and passes through the ligament to prevent damage to the neurovascular bundle (Fig. 3). Two sutures (PROLEN 1–0) are then placed on the sacrospinous ligament 2 cm from the ischial spine, at a 30° angle. The loop of the thread is removed with tweezers, and the second suture is medially applied for approximately 1 cm. The free ends are then fixed in the apical part of the

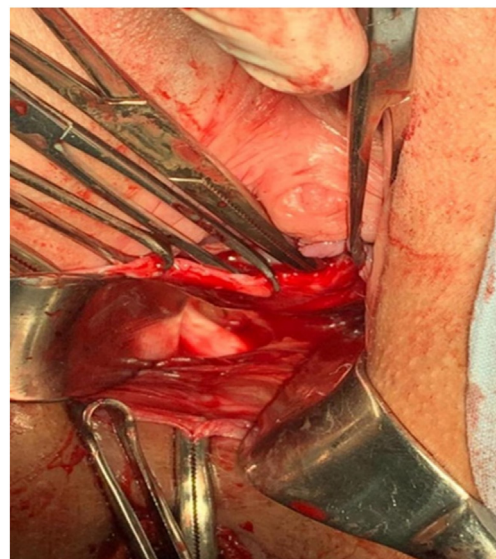


Fig. 2. Identification of the right coccygeal-sacrospinous ligament.

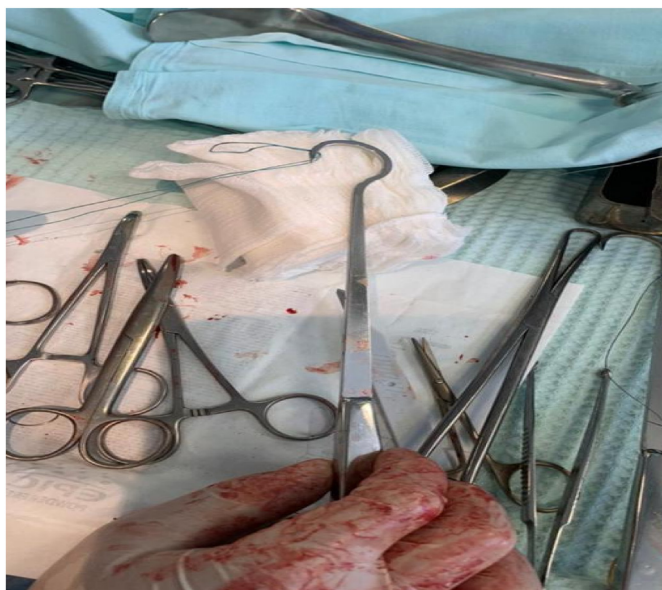

Fig. 3. Needle for sacrospinous fixation.

vaginal dome with the least fibrosis. Before colpex sutures are applied, the upper third of the vagina is sutured with a separate knotty vicryl and the pelvic floor is reconstructed. After the operation, a tampon is placed in the vagina for 12–18 h.

The needle has a round bar with a pointed end, on which there is a hole for the thread. The working part sits at a 30° angle from the handle and passes through the ligament to prevent damage to the neurovascular bundle. The closest analog to the fixation needle is the Miya suture hook.²⁰ Reshaping the sacrospinous ligament at a 30° angle reduces the risk of damage to the nervus pudendus and the inferior gluteal artery, yet does not decrease the degree of fixation of this ligament.

3. Advantages and disadvantages

Modern pelvic surgery requires significant innovation, the benefits of using this needle include the following:

- 3.1 The working part sits at a 30 angle from the handle, which makes it easier to pass through the ligament;

- 3.2 The needle is made of solid metal. It has a diameter of 4 mm and is fixed to the handle. Most reported cases of needle breakage are related to diameter size;
- 3.3 The 30 angle prevents deep immersion of the needle and prevents damage to the pudendal nerve and the inferior gluteal artery;
- 3.4 The length and diameter of the handle (6 mm) prevent changes in direction or bending;
- 3.5 Visual control of the fixation technique;
- 3.6 The sharp end of the needle separates fabric fibers and doesn't cut them;
- 3.7 The trajectory of the needle through the fabric corresponds to its curvature.

Disadvantages of this design can be attributed to the difficulty of changing the angle of the working part, which could puncture the ligament.

4. Clinical case

A 57-year-old female was admitted with complaints of a foreign sensation in the perineal region. She underwent transvaginal hysterectomy of the uterus for POP-Q IV pelvic prolapse in 2017. She had complaints of a foreign sensation in the perineal region and incomplete emptying of the bladder in 2018. The patient had a history of hypertension 2°, 2 stages, risk 3, type 2 diabetes mellitus; menarche at the age of 13, menstruation lasting 5–6 days, moderate, painless, menstrual cycle of 26 days, menopause as of 10 years. The patient had 3 total pregnancies ending with one birth and two abortions (no complications). To assess the intensity of blood flow to the pelvic organs, laser Doppler flowmetry of the anterior and posterior walls was performed using a LAKK-01 apparatus; a decrease in the intensity of pelvic floor microcirculation was observed. A unified design system was used to assess the feasibility of surgically correcting genital prolapse, which accounted for comorbid pathologies.²¹ Sacrospinous fixation was proposed.

Gynecological examination revealed that the external genital organs developed correctly, the vaginal stump is located outside the genital slit (POP-Q III grade), the vaginal dome was 4 cm long in the submucosal layer, and fibrosis of the connective tissue was determined. Within 3 months, the patient underwent rehabilitation to reduce fibrosis and improve blood flow in the vaginal walls. Anterior colporrhaphy was performed with native tissues and pexy. A needle was used according to the Miyazaki technique for sacrospinous fixation (Fig. 4).

Recovery is the primary goal during the postoperative period. The patient was discharged on the 3rd day. Control examination was performed after 15 days, with satisfactory results. Gynecological status

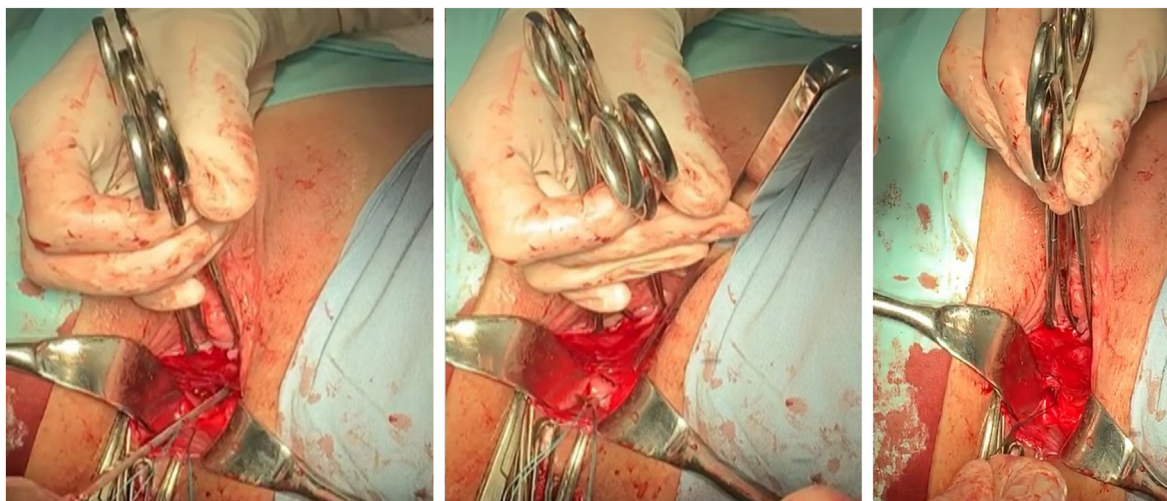


Fig. 4. Miyazaki needle fixation method.

shown that the external genital organs correctly developed, the genital slit was closed, and no sensation was experienced in the vaginal walls when straining.

5. Discussion

Sacrospinous fixation using the Miyazaki technique is an effective and safe method for correcting apical prolapse. Each patient requires a different treatment that must account for comorbid pathologies, the degree of prolapse, and individual risks of surgical complications and recurrence. After a hysterectomy, 3.6 per 1000 people require surgical correction of prolapse, while every third experiences apical prolapse.²² The FDA's 2019 decision has increased interest in surgery using native tissues. Therefore, reconstruction with native tissues and sacrospinous fixation could be a primary treatment method. The main complaint in most patients is a foreign sensation in the perineal region. However, some experience urinary and fecal incontinence which can delay the seeking of medical help. From December 2020 to May 2021, 10 sacrospinous fixations were performed with this needle according to Miyazaki's technique. The needle is easy to use and the pointed tip allows for penetration of the sacrospinous ligament for direct imaging. Therefore, using a needle for sacrospinous fixation is a new tool for minimally invasive technologies used in pelvic prolapse surgery. Additionally, this needle demonstrated high clinical efficiency under medical and economic controls.

This needle was designed to improve its practical properties when affixed to the walls of the vagina, however, it has also reduced injury risk and discomfort during surgery. The primary advantage of this needle is its ease of use. It also remains sharp after multiple insertions, is easier to control the position, and can move smoothly through tissues. The curvature of the needle ensures that it is stable and used gently. Disadvantages include the inability to move the needle handle on its own, which could pierce the ligaments.

Future improvements might include optimization of the handle to ensure movement of the working part during its use.

6. Conclusion

Using a needle for sacrospinous ligament fixation based on the Miyazaki technique can be used as the primary treatment option for pelvic organ prolapse.

Ethics approval and consent

All procedures performed relating to human research are compliant with institutional and national research ethics committees and the declaration of Helsinki and patient Consent.

Contributions

AG: Conceptualization and methodology; VN: Supervision; II:

Investigation and imaging; RA and EM: Resources; WJ and SX: Review & Editing.

Declaration of competing interests

The authors declare no conflicts of interest.

References

1. Swift S. The distribution of pelvic organ support in a population of female subjects seen for routine gynecologic health care. *Am J Obstet Gynecol.* 2000;183:277–285.
2. Friedman T, Eslick GD, Dietz HP. Risk factors for prolapse recurrence: systematic review and meta-analysis. *Int Urogynecol J.* 2018;29:13–21.
3. Marchianni M, Bracco GL, Checcucci V, et al. True incidence of vaginal vault prolapse: thirteen years of experience. *J Reprod Med.* 1999;44:678–684.
4. Buyanova SN, Shchukina NA, Zubova ES, et al. Prolapse of the genitals. *Russ Bull Obstet Gynecol.* 2017;17(1):37–45.
5. *Results of the Pilot Population Census.* Federal State Statistics Service; 2018. [Last accessed on 2019 Sep 9].
6. *World Population Ageing (Executive Summary).* United Nations Population Division; 2007. [Last accessed on 2014 Apr 29].
7. Ageing and Life Course: Interesting Facts about Ageing. World Health Organization. [Last accessed on 2013 Nov 23].
8. Singh SK, Sharma SK, Siddhanta A. Major correlates and socioeconomic inequalities in hysterectomy among ever-married women in India. *Indian J Community Med.* 2020; 45:127.
9. Ishchenko AI, Alexandrov LS, Ishchenko AA, et al. Multifocal fixation of mesh implants using combined laparovaginal access in patients with enterocele problems of gynecology. *Obstet Perinatol.* 2016;15(6):69–72.
10. Willy Davila, Gamal M. Ghoniem, et al. Pelvic Floor Dysfunction: A Multidisciplinary Approach. 2009th Edition G.
11. Gágyor D, Pilka R, Kudela M, et al. Sakrospinous fixation sec. Miyazaki - complications and long-term results. *Ceska Gynekol.* 2019;84(2):105–110.
12. Kudela M, Ondrová D, Pilka R, et al. Sacrospinous fixation of the prolapsed vagina after the Miyazaki hysterectomy procedure. *Ceska Gynekol.* 2004;69(6):493–497.
13. Popov AA, Krasnopolskaya IV, Tyurina SS, et al. Sacrospinal fixation in the treatment of women with genital prolapse in the era of mesh technology. *Russ Bull Obstet Gynecol.* 2013;13(2):36–41.
14. Yashchuk AG, Kulmukhametova NG, Luzina LV, et al. A method of surgical treatment of enterocele by vaginal access. Invention patent; 2007. Request No 2005118203/14, 14.06.2005.
15. Davila GW, Ghoniem GM, Kapoor DS, et al. Pelvic floor dysfunction management practice patterns: a survey of members of the international Urogynecological association. *Int Urogynecol J Pelvic Floor Dysfunct.* 2002;13(5):319–325.
16. Maher C, Feiner B, Baessler K, et al. Surgical management of pelvic organ prolapse in women (review). *Cochrane Database Syst Rev.* 2013;4:1–161.
17. Ng-Stollmann N, Fünfgeld C, Gabriel B, et al. The international discussion and the new regulations concerning transvaginal mesh implants in pelvic organ prolapse surgery. *Int Urogynecol J.* 2020;31(10):1997–2002.
18. Katrikh AZ, Ettarh R, Kahn MA. Cadaveric nerve and artery proximity to sacrospinous ligament fixation sutures placed by a suture-capturing device. *Obstet Gynecol.* 2017;130(5):1033–1038.
19. Karram MM, Ridgeway BM, Walters MD. Surgical treatment of vaginal apex prolapse. In: Walters MD, Karram MM, eds. *Urogynecology and Reconstructive Pelvic Surgery.* fourth ed. Philadelphia (PA): Elsevier Saunders; 2015:360–382.
20. Reprinted from Walters MD, Karram MM. *Urogynecology and Reconstructive Pelvic Surgery.* 2nd edition. St. Louis, MO: CV Mosby; 1999.
21. Yashchuk AG, Musin, Kazantseva EG. Unified design system for surgical correction for genital prolapse, taking into account comorbid pathologies. *Database Registration Certificate.* September 15, 2020. Request No 2020621524 or 02.09.2020.
22. Braga A, Serati M, Salvatore S, et al. Update in native tissue vaginal vault prolapse repair. *Int Urogynecol J.* 2020;31(10):2003–2010.